




## COMPLICATED CROWN-ROOT FRACTURES: TWO CASE REPORTS

Behiye BOLGUL<sup>1</sup>, Rukiye ARIKAN<sup>2</sup>, Öykü PEKER<sup>3\*</sup>

<sup>1</sup>Department of Pediatric Dentistry, Faculty of Dentistry, Hatay Mustafa Kemal University, Hatay, Türkiye  
[behiyebolgul@hotmail.com](mailto:behiyebolgul@hotmail.com) (  <https://orcid.org/0000-0003-3833-3444>)

<sup>2</sup>Department of Pediatric Dentistry, Faculty of Dentistry, Hatay Mustafa Kemal University, Hatay, Türkiye  
[rukiyearikan6@gmail.com](mailto:rukiyearikan6@gmail.com) (  <https://orcid.org/0000-0001-7445-0459>)

<sup>3</sup>Department of Pediatric Dentistry, Faculty of Dentistry, Hatay Mustafa Kemal University, Hatay, Türkiye  
[oykupeker@hotmail.com](mailto:oykupeker@hotmail.com) (  <https://orcid.org/0000-0002-3698-6225>)

Received: 09.03.2023

Case Report

Accepted: 17.04.2023

\*Corresponding author

### Abstract

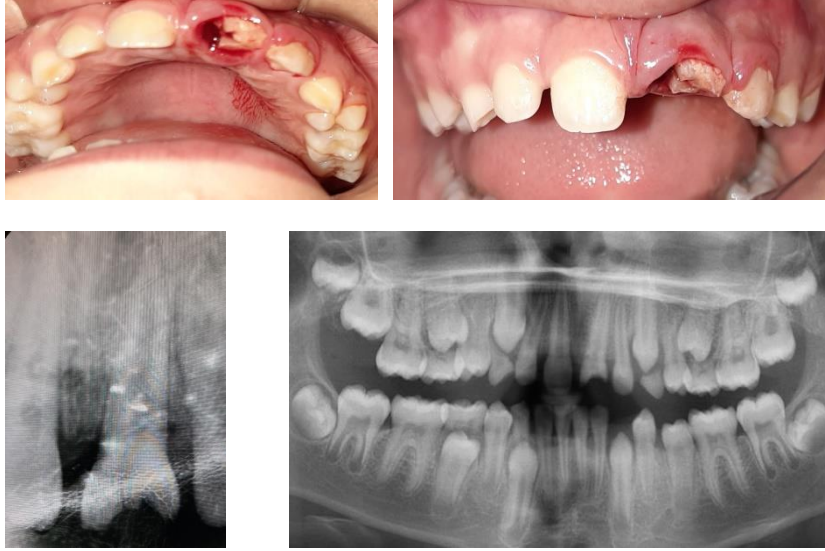Dentoalveolar traumas mostly occur in children and adolescents as a result of falls, fights, and vehicle accidents (Ellis, Moos & El-Atlar, 1985; Baratieri, Monteiro & Andrada, 1990). Traumatic dental injuries can cause a variety of damage, ranging from minimal enamel loss to complicated fractures involving the pulp (Andreasen, Andreasen & Andersson, 2007). Fractures involving enamel, dentin and cementum are called crown-root fractures. It can be classified as a complicated or uncomplicated crown-root fracture according to whether the trauma involves the pulp (Andreasen & Andreasen, 1994). 80% of these traumas are related to the central incisors and 16% to the lateral incisors (Andreasen & Ravn, 1972). Treatment options depend on the level of the fracture line and the amount of tooth tissue remaining. Depending on the pulpal conditions, the amount of tooth eruption, whether there is a tooth piece compatible with the remaining tooth structure, the length and morphology of the root, the situation in the aesthetic region and the patient's aesthetic expectation (Andreasen & Ravn, 1972; Kızıoğlu & Karayılmaz, 2007) Direct capping, pulpotomy, or root canal treatment are among the treatment options that can be applied. In these case reports, it was seen that successful results were obtained with correct diagnosis and treatment options even in cases that seem quite complicated and have low probability of success, and treatment options that can be applied after late trauma were stated.

**Keywords:** Complicated crown-root fracture, Dental trauma, Young permanent teeth

### 1. Introduction

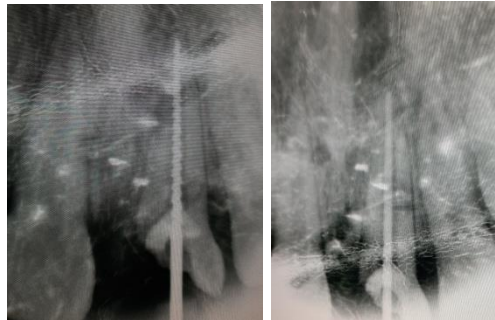
Many treatment methods are recommended for aesthetic restorations in teeth with crown root fractures, such as osteotomy, osteoplasty, orthodontic or surgical extrusion by removing the mucogingival flap, gluing the broken original piece, ceramic or metal crowns, and post-core applications. Another form of treatment is; It is the restoration of the tooth with restorative material such as composite resin or prosthetically (Yılmaz et al., 2008; Sapna et al., 2014).

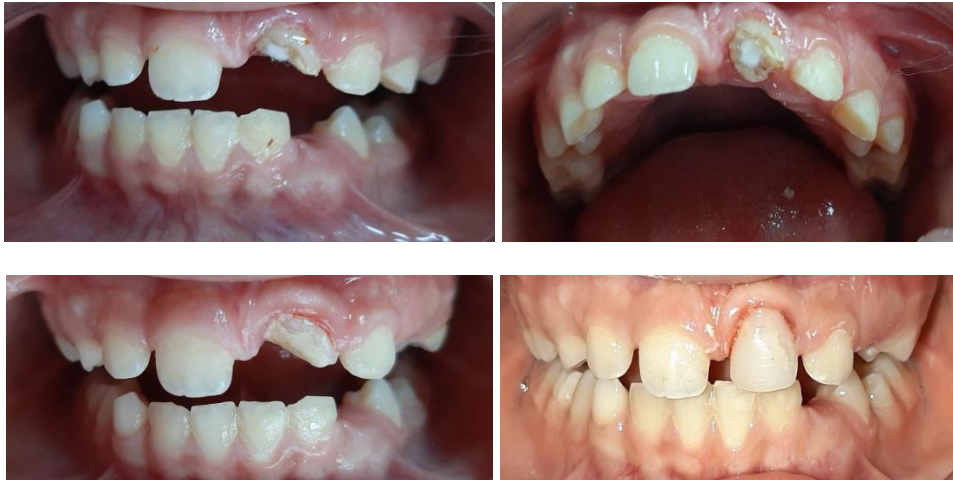In these two case reports, patients and their parents have been informed. And informed consent has been obtained. After the process root-canal treatment, aesthetic restoration and patient follow-up of maxillary central incisors with complicated crown-root fracture as a result of trauma are presented.

**CASE:1****Pre-operative intraoral radiographs and photos**

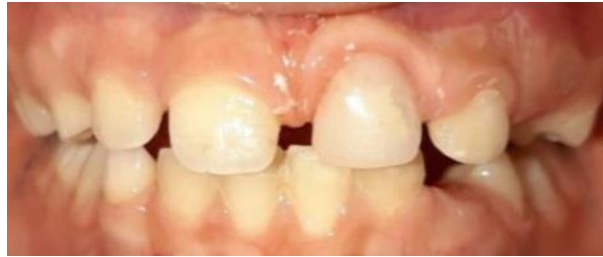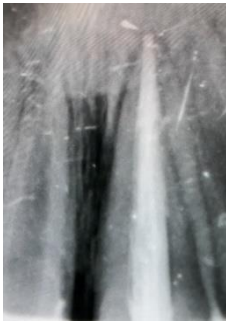
A 12-year-old male patient applied to our clinic due to a tooth fracture caused by trauma to his tooth. In the anamnesis taken and the intraoral examination, it was determined that there was a complicated crown-root fracture in the tooth, and it was seen that the fracture line ended 2 mm below the gingival level in the intraoral films.

After local anesthesia was applied, the mobile broken piece was removed, and gingivectomy and gingivoplasty were performed under anesthesia. After the bleeding was controlled, the tooth extirpation process was completed and the cavity was closed with glass ionomer (R&D Series Nova Glass-L) cement. One week later, the patient was called again and root canal treatment was completed. After the cavity under the gingiva was restored with glass ionomer cement, permanent aesthetic restoration of the tooth was completed using a strip crown. For application, 37% orthophosphoric acid (K-Etchant Syringe Gel, Okayama, Japan), self-etch adhesive (Xs –Bond 7 self-etching light-cured bonding agent Gyeonggi-do, Korea), Palfique estelite paste (Tokuyama Dental Corp. Japan) composite was used. Finally, Super –Snap Rainbow Technique Kit (Shofu INC, Kyoto, Japan) was used for composite polishing and finishing.

**2nd seance intraoral radiographs and photograph**



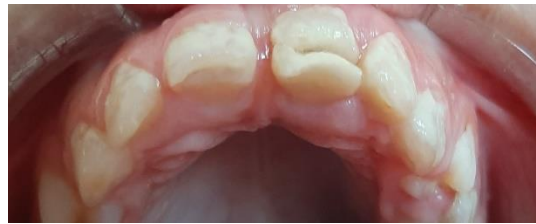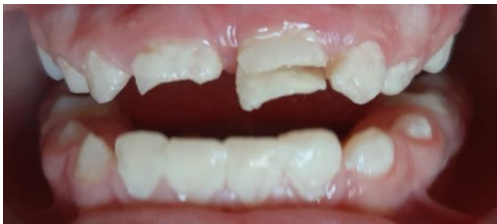In the clinical and radiographic control performed three months later, it was determined that there were no symptoms, periapical and periodontal pathology in the related tooth. The follow-up of the patient is still continuing in our clinic.

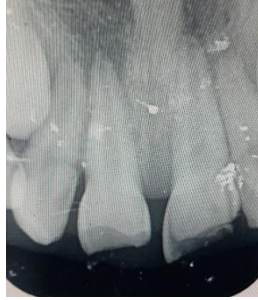

3rd month radiograph      3rd month intraoral photograph

## CASE:2

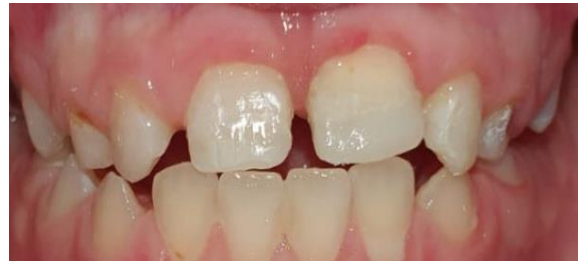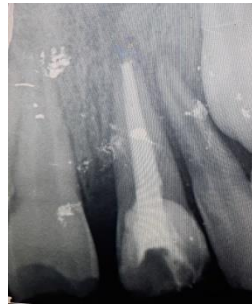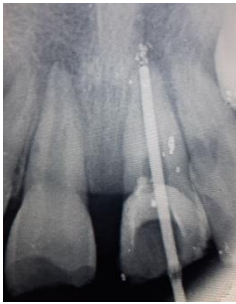### Pre-operative intraoral radiographs and photographs





A 9-year-old female patient was admitted to our clinic with the complaint of tooth fracture as a result of trauma. In the anamnesis, it was learned that ten days had passed since the trauma, and the patient had severe pain during this period. In the clinical examination, the complicated crown-root fracture was observed in tooth 21 and an uncomplicated crown fracture in tooth number 11. No luxation-mobility was observed in any of the related teeth. In the intraoral films, it was seen that the fracture line in tooth number 21 extended under the gingiva palatal. After the broken piece of tooth number 21 was removed under anesthesia, extirpation, which is the first stage of root canal treatment, was performed and the related tooth was closed with glass ionomer filling material. Since there was no pulpal opening in tooth number 11 in the same session, permanent aesthetic restoration was completed in a single session.

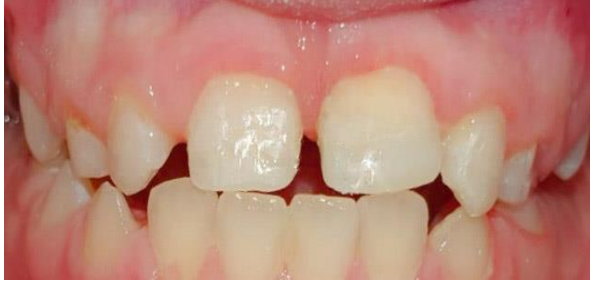At the appointment two weeks later, the root canal treatment of tooth number 21 was completed. The gingiva in the palatal region was observed as healed and formed. The permanent aesthetic restoration of the tooth, which was restored with glass ionomer cement up to the gingival level, was also completed in the same session. For application, 37% orthophosphoric acid (K-Etchant Syringe Gel, Okayama, Japan), self-etch adhesive (Xs –Bond 7 self-etching light-cured bonding agent Gyeonggi-do, Korea), Palfique estelite paste (Tokuyama Dental Corp.) Japan) the composite was used. Finally, Super –Snap Rainbow Technique Kit (Shofu INC, Kyoto, Japan) was used for composite polishing and finishing.



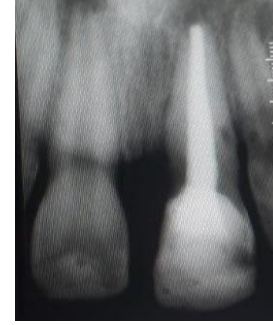2nd seance intra-oral radiographs

Post-operative intraoral photograph

In the clinical and radiographic control performed three months later, it was determined that there were no symptoms and pathologies in the teeth. The follow-up of the patient is still continuing in our clinic.



3rd month intraoral photograph



3rd month periapical radiograph

## 2. Discussion

The treatment method to be performed in complicated crown-root fractures varies according to the open time of the pulp tissue, the level of perforation, the level and dimensions of root development. The time between trauma and initiation of treatment plays a key role in success (Alaçam, 2012; Flores et al., 2007). Intervention within the first few minutes following trauma is very important for keeping the tooth vital. In the period when it is applied late as a result of trauma, the probability of keeping the tooth vital decreases gradually.

The size of the pulp opening is also important in determining treatment options in complicated crown-root fractures. According to the amount of pulp opening, direct capping, amputation or root canal treatment are among the treatment options that can be applied (Burke, 1991; Tulunoğlu & Görduysus, 1997). Since the size of the pulp opening seen in these cases was not at a level that could respond positively to direct capping or amputation treatment, root canal treatment was applied to the related teeth. And successful results were obtained in long-term follow-up.

A sealed aesthetic restoration is very difficult in traumatized young permanent teeth when the fracture line extends below the gingival level (Olsburg, 2002). In these cases, the permanent restoration of the teeth could be completed with the composite restoration, as the necessary isolation for an aesthetic restoration could be provided and the gingival bleeding could be easily stopped.

In teeth with complicated crown-root fracture, if the fractured part of the tooth fits adequately, it can be replaced if deemed appropriate after endodontic, periodontal and occlusal evaluations (Vilela et al., 2003; Öz, Haytaç & Toroğlu, 2006). In our cases, reattachment technique was not applied because both comminuted fractures were present and the fractured fragments did not have sufficient compatibility, and permanent aesthetic restorations of the teeth were performed with composite resin.

## 3. Conclusion

Cases in which permanent aesthetic restorations are made with composite restorations can be a good alternative to reattachment technique, prosthetic restorations, and implant treatments or to postpone these treatments for a while, in terms of ease of application, easy acceptance by the patient in terms of functionality and aesthetics, and lower cost. In addition, satisfactory aesthetic and functional results were obtained in both cases restored with self-etch adhesive systems and composite resins without intracanal post-application after endodontic treatment. Long-term follow-up of the cases continues.

## References

Alaçam, A. L. E. V. (2012). Travma Nedeniyle Oluşan Diş Yaralanmalarını ve Tedavileri, Bölüm 28: 985-1058.



- Andreasen JO, Andreasen FM, Andersson L. (2007) Crown-root fractures. Textbook and Color Atlas of Traumatic Injuries to the Teeth. 4th ed. Oxford: Blackwell; :314-36.
- Andreasen, J. O. (1993). Textbook and color atlas of traumatic injuries to the teeth. *Munksgard. Copenhagen, 155*, 172-173.
- Andreasen, J. Q., & Ravn, J. J. (1972). Epidemiology of traumatic dental injuries to primary and permanent teeth in a Danish population sample. *International journal of oral surgery, 1(5)*, 235-239.
- Baratieri, L. N., Monteiro, S., & de Andrada, M. C. (1990). Tooth fracture reattachment. *Quintessence Int, 21(4)*, 261-270.
- Burke, F. J. (1991). Reattachment of a fractured central incisor tooth fragment. *British dental journal, 170(6)*, 223-225.
- Ellis III, E., Moos, K. F., & El-Attar, A. (1985). Ten years of mandibular fractures: an analysis of 2,137 cases. *Oral surgery, oral medicine, oral pathology, 59(2)*, 120-129.
- Flores MT, Andersson L, Andreasen JO, Bakland LK, Malmgren B, Barnett F. et al (2007). Guidelines for the management of traumatic dental injuries. *Dent Traumatol, :66-71*.
- Kırzioğlu, Z., & Karayılmaz, H. (2007). Surgical extrusion of a crown-root fractured immature permanent incisor: 36 month follow-up. *Dental Traumatology, 23(6)*, 380-385.
- Olsburgh, S., Jacoby, T., & Krejci, I. (2002). Crown fractures in the permanent dentition: pulpal and restorative considerations. *Dental Traumatology, 18(3)*, 103-115.
- Öz, İ. A., Haytaç, M. C., & Toroğlu, M. S. (2006). Multidisciplinary approach to the rehabilitation of a crown-root fracture with original fragment for immediate esthetics: a case report with 4-year follow-up. *Dental Traumatology, 22(1)*, 48-52.
- Sapna, C. M., Priya, R., Sreedevi, N. B., Rajan, R. R., & Kumar, R. (2014). Reattachment of fractured tooth fragment with fiber post: a case series with 1-year followup. *Case reports in dentistry, 2014*.
- Tulunoğlu, I. F., & Görduysus, Ö. (1997). A simple method for the restoration of fractured anterior teeth. *Journal of Prosthetic Dentistry, 78(6)*, 614-615.
- Vilela, E. A., Baratieri, L. N., Caldeira de Andrada, M. A., Monteiro Jr, S., & Medeiros de Araújo, J. (2003). Tooth fragment reattachment: fundamentals of the technique and two case reports. *Quintessence International, 34(2)*.
- Yılmaz, Y., Zehir, C., Eyuboglu, O., & Belduz, N. (2008). Evaluation of success in the reattachment of coronal fractures. *Dental traumatology, 24(2)*, 151-158.